Neuroscience 2nd TBL (25 MCQs)

1- Examination of a 55 year-old male patient was significant for increased tone in the left arm. The resistance was stronger at the beginning of the range of motion. It increased with higher speed of mobilization. Which of the following is applicable to this patient's signs?

A. Cog-wheel rigidity
B. Lead-pipe rigidity
C. Spasticity
D. Paratonia
E. Myotonia

Answer: C

2- Sleep disturbance and loss of appetite are symptoms of depression due to abnormality in which of the following brain areas?

A. Prefrontal cortex
B. Hypothalamus
C. Hippocampus
D. Temporal lobe
E. Amygdala

Answer: B

3- A 30 year-old man feels that his neighbors are able to read his mind. What type of condition is he suffering from?

A. Delusions of grandeur
B. Nihilistic delusion
C. Persecutory delusion
D. Delusion of reference
E. Thought broadcasting

Answer: E

4. Which part of the internal capsule transmits auditory fibers ?
A- anterior limb
B-posterior limb
C- Genu
D- retrolentiform
E- sublentiform

Answer: E

5- A 65 y/o hypertensive man presents to the emergency department with sudden onset of weakness on the left side of the body. Neurological examination revealed spastic paralysis involving the left half of the body and the lower part of the left face. There was complete sensory loss on the left side of the body. Babinski's sign was positive on the left side. An MRI was performed which is shown in the attached picture.
Which one of the following areas is involved in this case ?

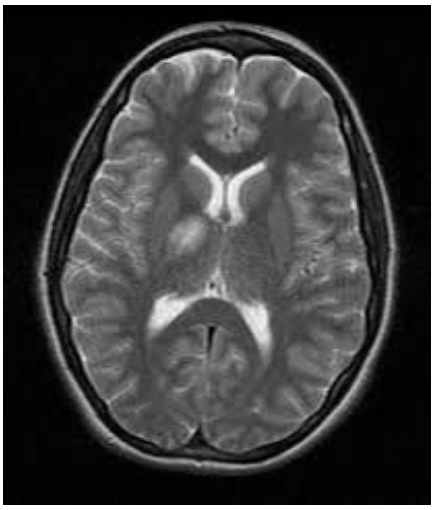

A. Right Anterior limb of the internal capsule
B. Right Posterior limb of the internal capsule
C. Right frontal lobe
D. Right frontal and parietal lobe

E. Right temporal lobe

Answer: B

6. A 60 y/o man was admitted to our emergency department for sudden onset abnormal movement in his right limbs during daily activities. The symptoms were alleviated during relaxation and completely eliminated during sleep. Neurological examination revealed involuntary proximal ballistic movement affecting both upper and lower limbs in the right side. An MRI was performed two days later which revealed an infarct involving which one of the following areas?

A. caudate nucleus
B. Thalamus
C. Subthalamus
D. Substantia nigra compacta
E. Putamen

Answer: C

07. A 21 year old male brought to the ER by his family members in a state of excitement, violent attitude, and insomnia for more than 24 hours. Upon examination, he was extremely agitated, sweaty and restless. His vital signs show tachycardia, high blood pressure and mild fever. His brother tells you that he has been very anxious lately because of his final exams next week. His past history is unremarkable, You suspect that he has taken a drug. Which of the following is most likely drug he has taken?

A. Alcohol
B. Marijuana
C. Methamphetamine
D. Gamma hydroxybutyric acid (GHB)
E. Alprazolam

Answer: C

08. Which one is a non-psychotic indication of typical antipsychotic drugs?

A. Preoperative sedation
B. Alcohol detoxification
C. Bulimia nervosa
D. Vasomotor symptoms of menopause
E. Narcolepsy

Answer: A

09. A 26 year old female patient with refractory depression was maintained on an antidepressant drug. She reports attacks of palpitation, shortness of breath, and headache whenever she eats cheese. Her blood pressure was also found to be high during these attacks. Which class of antidepressants is she most likely on?

A. Monoamine oxidase (MAO) inhibitors
B. Serotonin modulator
C. Selective serotonin reuptake inhibitors
D. Selective- NE reuptake inhibitor
E. Serotonin- NE reuptake inhibitor.
F. Atypical antidepressants.

Answer: A

10. A patient with acquired neurological damage manages to exhibit his teeth symmetrically upon request. However he cannot exhibit a symmetrical smile on the left side of the face after a joke. Which of the following is true for this case?

A. Voluntary facial paresis with damage on the right primary motor cortex.
B. Voluntary facial paresis with damage on the right thalamic pathway.
C. Emotional facial paresis with damage on the right primary motor cortex.
D. Emotional facial paresis with damage on the right thalamic pathway
E. Voluntary facial paresis with damage on the left primary motor cortex

Answer: D

11. Answering this question “In which country are the pyramids?” Correctly requires which memory system?

A. Episodic
B. Working
C. Immediate
D. Semantic
E. Procedural

Answer: D

12. Mr. John has suffered a stroke in the area shown in the figure. He occasionally disregards the left side of his body. Which one of the following cognitive tests would be advised after reviewing the patient's neuroradiological report?

A. Wisconsin's Sorting Task.
B. Go-No-Go Task.
C. False-Belief-Task.
D. Cross the line Task.
E. Word association Task.

Answer : D

13) Which of the following is most common in neonatal meningitis?
A) Group B streptococcus
B) Staphylococci aureus
C) Neisseria meningitidis type B
D) Coxsackie virus
E) Cryptococcus neoformans

Answer: A

14) Which of the following best applies to the viral agent shown in the microscopy image from the hippocampus?
A)Having specific geographic location (Middle East and Africa)
B) Affecting preferentially undernourished children
C) being more diffuse in winter
D) transmitted by mosquitoes of genus Anopheles
E) being preventable by live attenuated vaccine

Answer: E

15) The profile of CSF investigation presented here suggested what type of etiology ?

Opening pressure (mm H_2O)	200-500
WBC count (mm^3)	100-20,000 (mean 800)
WBC differential	>80% PMN
Protein (mg/dL)	100-500
Glucose (mg/dL)	≤40 (<40% of serum)
Gram stain (% +)	60-90

A) Bacterial
B) fungal
C) protozoal
D) tubercelar
E) Viral

Answer: A

16) During a neurosurgical procedure, an electrical stimulus applied to a part of the brain resulted in a discrete contralateral movement across a single joint. Which of the following brain areas was likely being stimulated?

A) Premotor cortex
B) Supplementary motor cortex
C) Globus pallidus externa
D) Cerebellar vermis
E) Primary motor cortex

Answer: E

17) The posterior inferior cerebellar artery (PICA) arises from which main stem artery?

A) Basilar artery
B) Posterior cerebral artery
C) Anterior cerebral artery
D) Middle cerebral artery
E) Vertebral artery

Answer: E

18) A 48 year old male presented to you with severe unilateral headache with accompanying nausea and vomiting. After exclusion of other causes, you make a diagnosis of migraine and consider to prescribe him sumatriptan. However, history of which one of the following diseases would prevent you from prescribing this drug?

A) Cardiac failure
B) Hepatotoxicity
C) Hypertension
D) Ischemic heart disease
E) Nephrotoxicity

Answer: D

19) A 70 year old male with new onset Parkinson's diseases was prescribed a combination of levodopa and carbidopa. One rationale of adding carbidopa is to minimize the development of adverse effects of levodopa. which one of the following adverse effects of levodopa would be effectively controlled by carbidopa?

A) Anxiety
B) Hallucinations
C) Hyperprolactinemia
D) Nausea and vomiting
E) Sleep disturbances

Answer: D

20) Which one of the following medications used for treatment of meningitis requires therapeutic monitoring of the blood concentration?

A) Cefatriaxone
B) Rifampin
C) Doxycycline
D) Linezolid
E) Vancomycin

Answer: E

21) An 88 year woman with Alzheimer disease dies of congestive heart failure. Examination of the brain autopsy bilateral atrophy of the gyri, particularly in the frontal, parietal and temporal cortex. What additional finding might be expected in the brain of this patient ?
a) atrophy of caudate
b) hydrocephalus ex voco
c) intraventricular hemorrhage
d) depigmentation of substantia nigra
e). periventricular patches of demyelination

Answer: B

22. A 70-year-old man has had stepwise loss of mental function for the past 10 years. He can no longer care for himself. Physical examination is unremarkable but he cannot remember any of 3 objects after 3 minutes. A chest X-ray shows cardiomegaly. Laboratory studies show a normal serum glucose and increased level of cholesterol and LDL. Which of the following is the most likely diagnosis?

A. Pick disease
B. Alzheimer
C. vascular dementia

D. Huntington disease
E. Mild cognitive impairment

Answer: C

23. A 42 year old man having a long history of productive cough presented to A&E with fever, increasing headache and drowsiness for the past one week. on physical examination her temperature is 38.6 degree. A head CT scan reveals a solitary 4cm diameter mass lesion with ring enhancement located in the left parietal lobe. A stereotactic biopsy is performed and a frozen section shows granulation tissue with adjacent collagenization, gliosis and edema. which of the following is the most likely diagnosis?

A. Bacterial abscess
B. Tuberculoma
C. Oligodendroglioma
D. B cell lymphoma
E. Thromboembolic infarct

Answer : A

24. A 68 year old homeless man is found in the street and is brought to the emergency room with severe dehydration and lethargy. He is rapidly treated with intravenous fluids but lapses into coma and expires. Examination of the brainstem at autopsy shows a soft lesion in the tegmentum of the pons. A section from the this region stained for the myelin with luxol fast blue is shown in the image. which of the following is associated with this disorder?

A. Hyperkalemia
B. Alcoholism
C. Hypertension

D. Multiple sclerosis
E. Viral infection

Answer : B

25. A 32 year old woman is brought to hospital after an episode of weakness. On examination, she has decreased strength in her left upper extremity and decreased light touch sensation over her right lower extremity. She has no decrease in cognition. A lumbar puncture is performed, and the CSF contains elevated levels of IgG and oligoclonal bands on gel electrophoresis. Which of the following pathological findings in the CNS is she most likely to have?
A. Gliosis with atrophy of caudate and putamen
B. Loss of pigmented neurons in the substantia nigra
C. Perivascular lymphocytes with plaques in periventricular white matter
D. Increased neurofibrillary tangles and neuritic plaques in the neocortex
E. Foci of multi-nucleated cells and macrophages in grey and white matter.

Answer: C

In case of any mistakes do not hesitate to contact the heads at :

- ★ Khaled Ahmed : kaaahmed@alfaisal.edu
- ★ Raidah Ayesha Razack : rrazack@alfaisal.edu